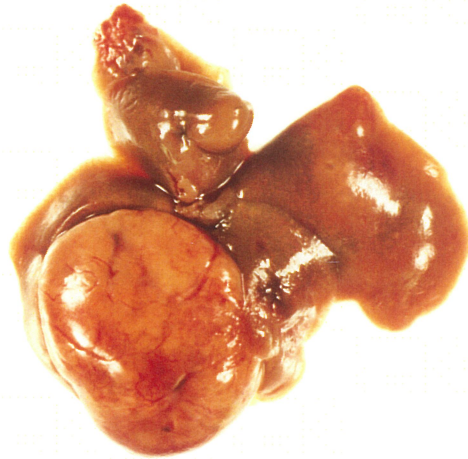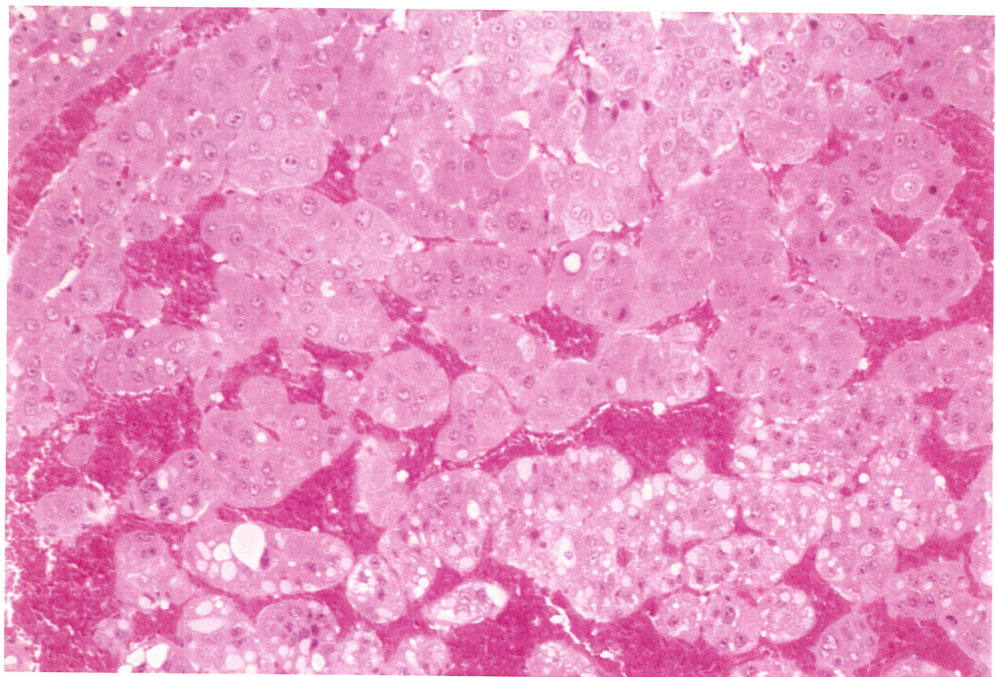
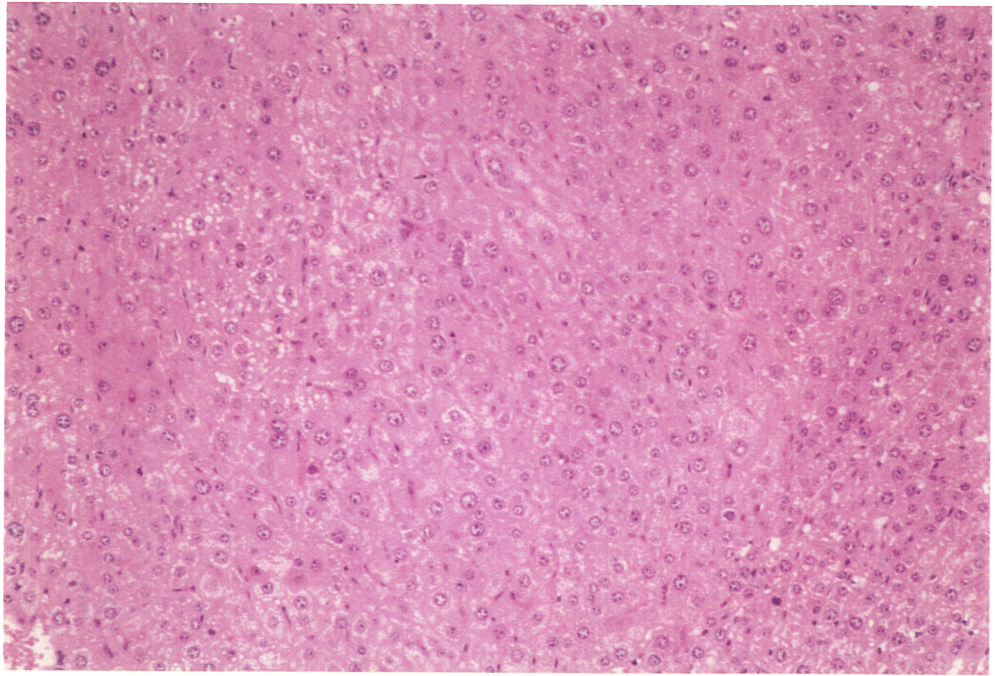


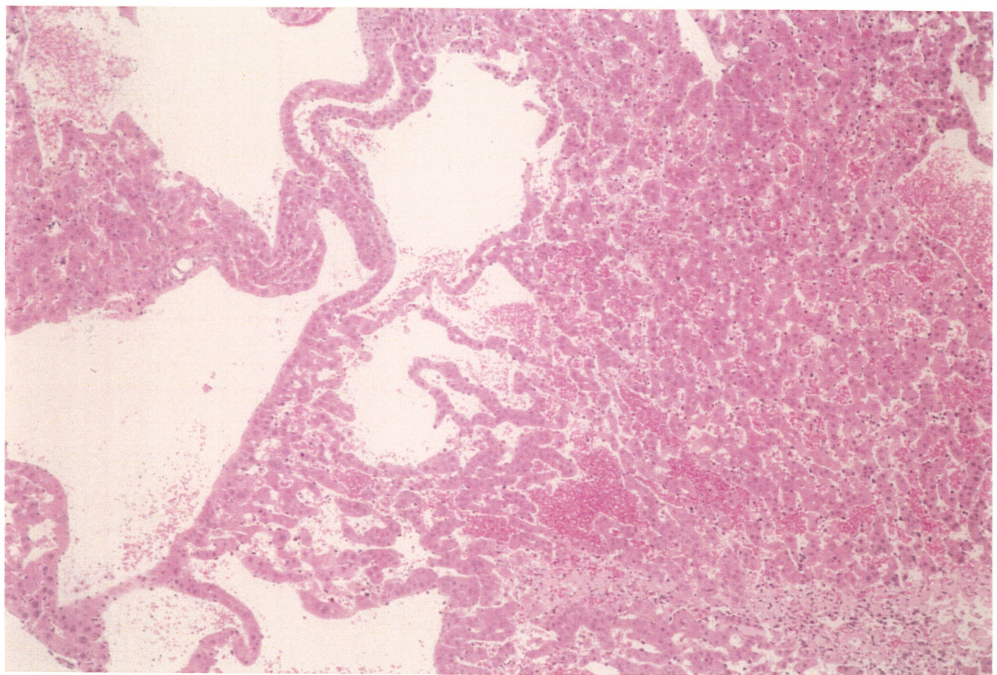
PHOTOGRAPH 29 LIVER, NODULE
MOUSE, MALE, 8000ppm, ANIMAL NO.0064-1340



PHOTOGRAPH 30 LIVER, HEPATOCELLULAR CARCINOMA
MOUSE, MALE, 8000ppm, ANIMAL NO.0064-1339 (H.E., X150)



PHOTOGRAPH 31 LIVER, HEPATOCELLULAR ADENOMA
MOUSE, FEMALE, 2000ppm, ANIMAL NO.0064-2203 (H.E., X150)



PHOTOGRAPH 32 LIVER, ANGIECTASIS
MOUSE, MALE, 8000ppm, ANIMAL NO.0064-1324 (H.E., X60)